



Managing the AVF that fail to mature

Dr. Supachoke maspakorn, Dr. Chanawit Sitthisombat
CVT and vascular team, Chiang-rai regional hospital



Primary failure of AV access

**Primary failure = early failure =
failure to mature = immature =
maturation failure**

“as an AV fistula that is never usable for
dialysis or that fails within three months of use”

“

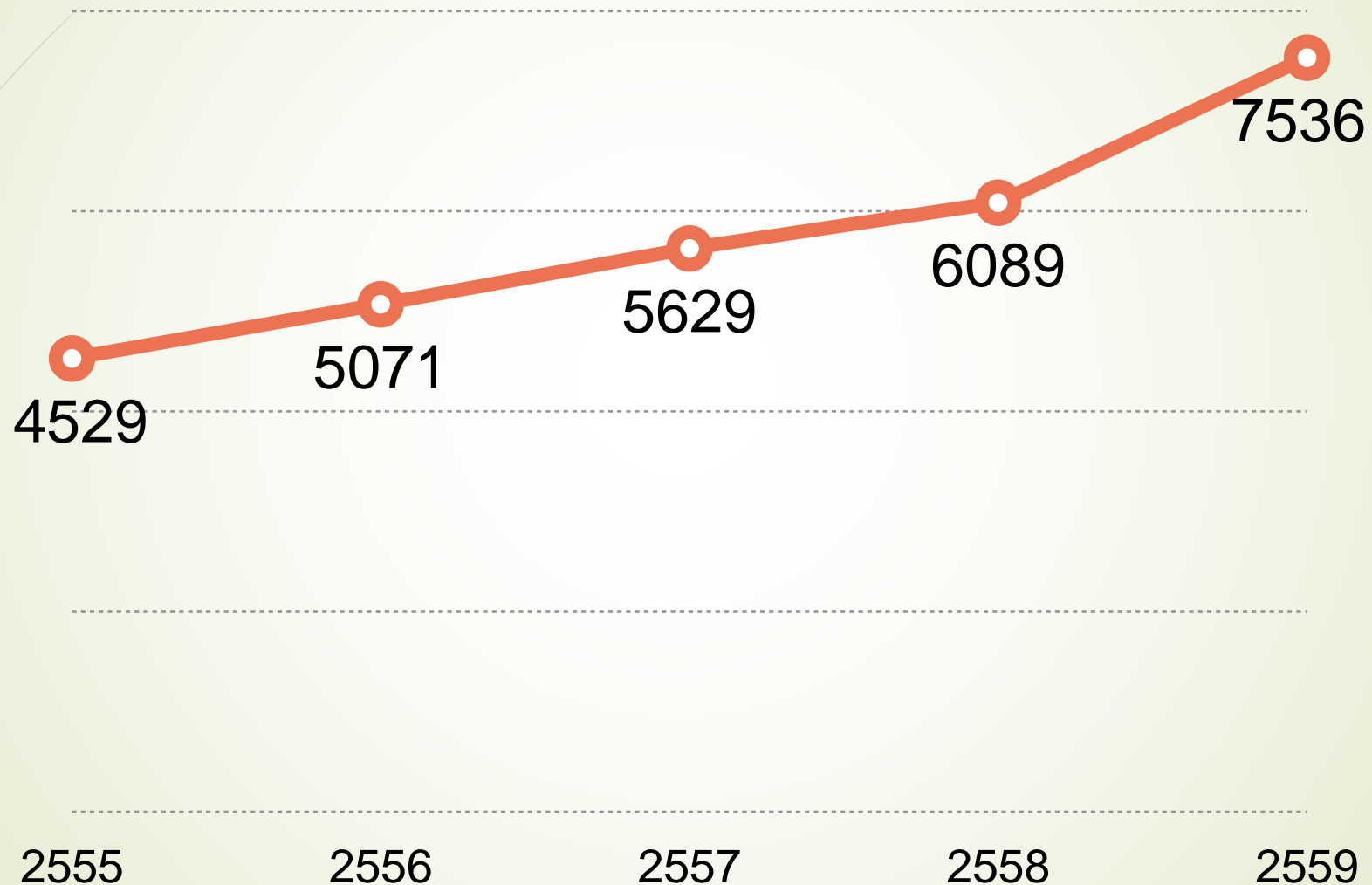
*Inability to reliably
cannulate an autogenous
AV access for dialysis*

”

“The vessel must increase in diameter to accommodate cannulation, and the vessel wall must thicken to permit repeated cannulation”

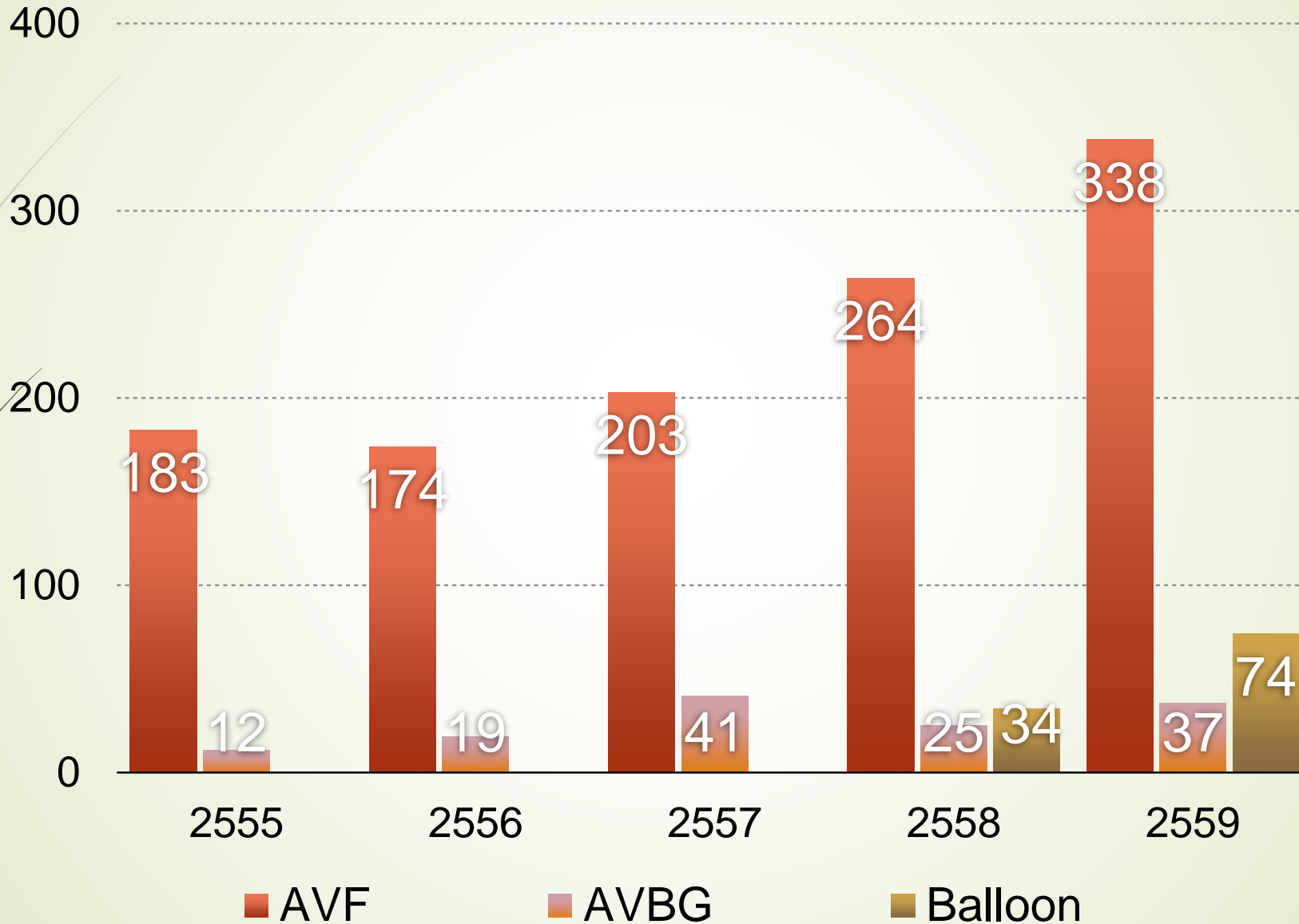
“Fragile, immature veins that have not become arterialized sufficiently to withstand the trauma of repeated cannulations may lead to hematomas around the needle access site”

สถิติหน่วยไตเทียม Hemodialysis



โรงพยาบาลเชียงรายประชานุเคราะห์
Chiangrai Prachanukroh Hospital

Vascular Access

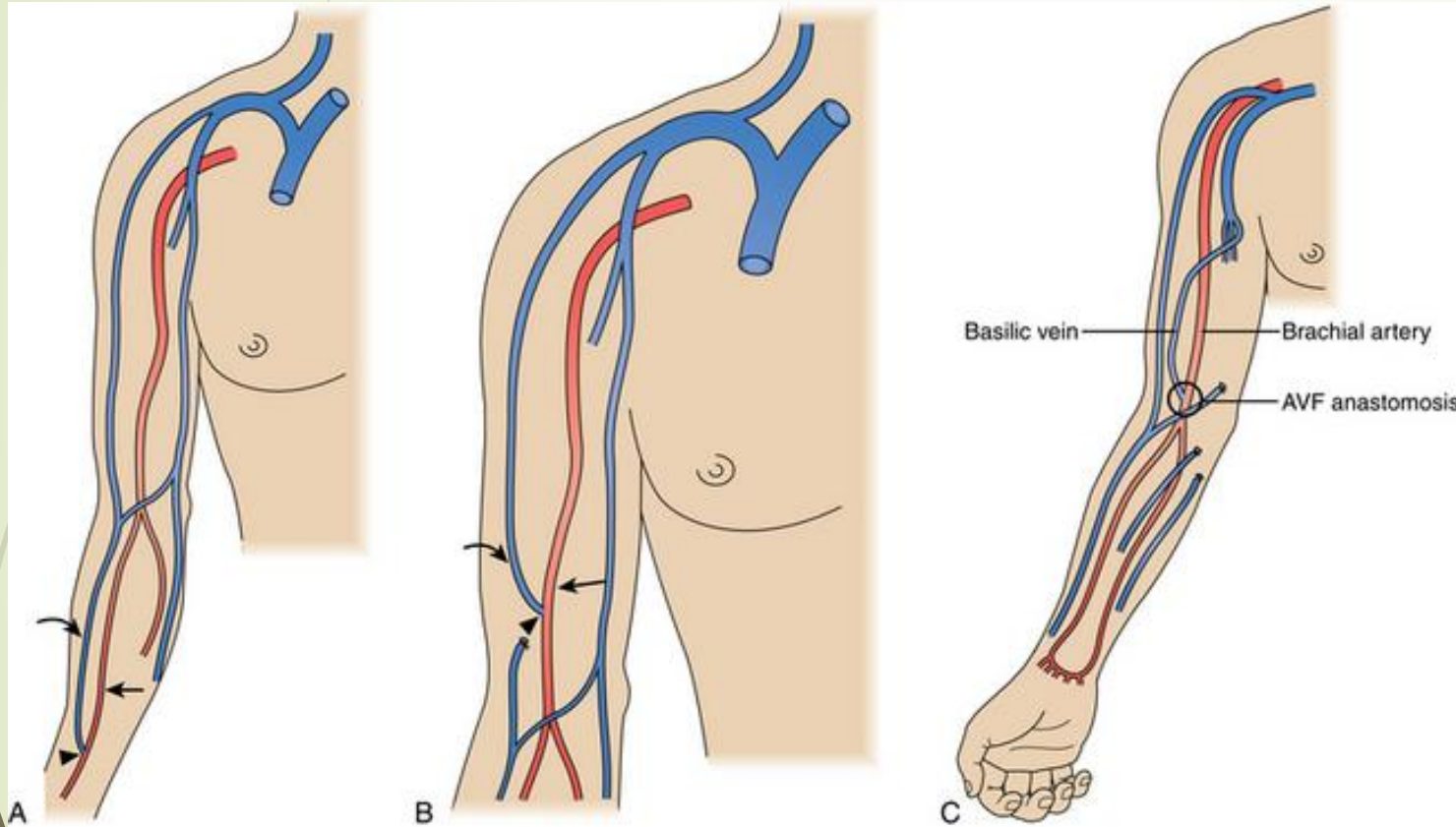


Incidence

- Older studies reported primary failure rates ranging from 10 to 25 percent but in more contemporary reports, the incidence has been higher, ranging from 20 to 60 %.

1. Allon M, Robbin ML , *Kidney Int.* 2002;62(4):1109.
2. Robbin ML, Chamberlain NE, *Radiology.* 2002;225(1):59.
3. Dember LM, Beck GJ, *JAMA.* 2008;299(18):2164.
4. Hodges TC, Fillinger MF, *J Vasc Surg.* 1997;26(6):1009.
5. Kalman PG, Pope M, *J Vasc Surg.* 1999;30(4):727.
6. Ascher E, Gade P, *J Vasc Surg.* 2000;31(1 Pt 1):84.
7. Hye RJ, Wolf YG, *Ann Vasc Surg.* 1994 Nov;8(6):578-82.
8. Lok CE, Oliver MJ, *Semin Dial.* 2003;16(3):189.
9. Hernandez T, Saudan, *Nephron Clin Pract.* 2005;101(1):c39.
10. Patel ST, Hughes J, *J Vasc Surg.* 2003;38(3):439.
11. Lok CE, Allon M J, *Am Soc Nephrol.* 2006;17(11):3204.
12. Ohira S, Kon T, *Hemodial Int.* 2006;10(2):173.
13. Sun Cheol Park, Seung Yeon Ko *Ann Surg Treat Res.* 2016 May;90(5):272-278. (MF = 24.8%)

Incidence



Among the three most commonly created AV fistulas, the primary failure rate for the brachial-basilic transposed fistula has been reported to be the lowest, followed by the brachial-cephalic and then the radial-cephalic with the highest rate.

High

Low


Objective criteria for maturation

- ➡ **The rule of “6”** = 6 weeks after the AV fistula has been placed, the fistula should:
- Be able to support a blood flow of 600 mL/min
 - Be at a maximum of 0.6 cm from the surface
 - Have a diameter greater than 0.6 cm

(KDOQI guideline 2006)



Risk factors for primary failure

- 
- Obesity
 - Older age
 - Female gender
 - Ethnicity other than Caucasian
 - Cardiovascular disease
 - Diabetes
 - Thrombophilia
 - Surgeon experience

Pre-existing lesions

Vascular stenosis

Inflow artery stenosis and small artery

Focal venous stenosis

Diffuse venous stenosis and small vein

In series that have been reported, proximal venous stenosis in 4-59 % and central venous stenosis in 2.6-9 % of cases.

Most surgeons feel, based upon evidence presented in the literature, that a vein smaller than 2.5 mm is inadequate for access creation.

Accessory vein and side branch

Juxta-anastomotic stenosis

Stenosis occurring within the first 3 to 4 cm of the AV fistula, immediately adjacent to the arterial anastomosis



Pre-existing Inflow artery stenosis and small artery or diffuse stenosis

- More likely to occur at radial artery
- Had 2 studies on diffuse radial artery stenosis that correct with balloon angioplasty.
- The major complication to be expected is rupture of the artery.
- PTA treatment should be accomplished with either a 3.5 or 4 mm balloon.
- Using a long balloon (10 mm) would also be an advantage.



Pre-existing venous stenosis

- Balloon assisted maturation (BAM) is a technique that has been used to treat AV fistulas that are unusable because of diffusely small caliber veins.
- BAM is becoming increasingly popular, despite few evidence-based studies and no randomized trials.
- The major complication associated with this procedure has been venous rupture. (an endothelial tear that occurs at the shoulder of the balloon)
- Use of a long angioplasty balloon, 10 cm in length.
- Arterial inflow should all be manually obstructed during the entire process from balloon dilatation through complete balloon deflation.
- It is important that PTA of a long segment of vein proceeds from proximal to distal (opposite the direction of flow).



Balloon assisted maturation (BAM)

- Aggressive approach to salvage non-maturing arteriovenous fistulae: USA, J Vasc Access. 2009
- The patients were divided into two groups:
 - class 1 AVF that were 6-8 mm in diameter but > 6 mm deep
 - class 2 small AVF that had size 2-5 mm
- The number of procedures required to attain the treatment goal for class 1 and class 2 cases was 1.6 and 2.6, respectively. (in 5-7 weeks)
- Successful fistula maturations were achieved in 118/122 patients.
- Primary patencies of 17 and 39% at 6 months
- Secondary patencies of 72 and 77% at 12 months, 53 and 61% at 24 months, and 42 and 32% at 36 months



Balloon assisted maturation (BAM)

- Balloon angioplasty to facilitate autogenous arteriovenous access maturation: USA, Semin Vasc Surg. 2011
- 373 patients/1019 BAM
- 2-4 weeks after creation AVF
- Inflow and juxta-anastomotic segments were dilated to 4 mm, the AVF was dilated to 4 to 6 mm
- Subsequent treatments took place at 2-4 weeks intervals with patients receiving a mean of 2.7 sequential dilatations
- The goal was to achieve a forearm AV fistula diameter of 8 to 10 mm and an upper-arm AV fistula diameter of 10 to 16 mm.
- A usable AV fistula was created in 94 percent of the 373 cases.



Accessory vein and side branch

- The first step is to rule out downstream stenosis. (collateral vessels)
- The next step is to decide its significance: judged by three criteria = size, flow, and changes that occur with manual occlusion.
- Once it has been determined that an accessory vein is impeding the maturation of the AV fistula, it can be obliterated by surgical ligation (direct through the skin, or open incision) or the percutaneous placement of an embolization coil.
- One study found that preoperatively detected accessory veins with a **diameter >70 percent** of the cephalic vein diameter had a sensitivity, specificity, positive predictive value, and negative predictive value of 80, 100, 100, and 91 percent for radial-cephalic AV fistula nonmaturation.

Juxta-anastomotic stenosis

Choice

- Open surgery: proximalization, PTFE interposition graft
- Transluminal angioplasty

Endovascular versus surgical preemptive repair of forearm arteriovenous fistula juxta-anastomotic stenosis: analysis of data collected prospectively from 1999 to 2004. Verona Italy, *Clin J Am Soc Nephrol.* 2006;1(3):448.

- 64 AV fistulas with >50 percent venous juxta-anastomotic stenosis
- 21 surgically (11 with proximal neo-anastomosis and 10 with PTFE interposition graft) and 43 by PTA
- Initial procedural success was 100 % for surgery and 95 % for PTA
- The restenosis rate was significantly **better for surgery** compared with PTA (0.168 versus 0.519 events/AV-fistula-year)
- The cost profile also was similar for the two procedures
- PTA does not exclude the possibility of a later surgical correction, if required, a reasonable approach would be to perform a PTA first, reserving the surgical approach as a back-up in case of failure.


Research

- Suwon, Republic of Korea. Clin Radiol. 2013 Jun;68(6):e309-15.
- To evaluate the anatomical causes of maturation failure; collected data on 141 cases of primary AV fistula failure.
- All cases in this cohort were found to have significant anatomic causes for their failure to mature.
- The site of the stenotic lesions were classified into six categories based upon location:
 - (1) native artery
 - (2) arteriovenous anastomosis
 - (3) juxta-anastomotic vein***** 65.2%
 - (4) cannulation zone
 - (5) distal venous outflow (beyond the cannulation zone)
 - (6) central venous system.

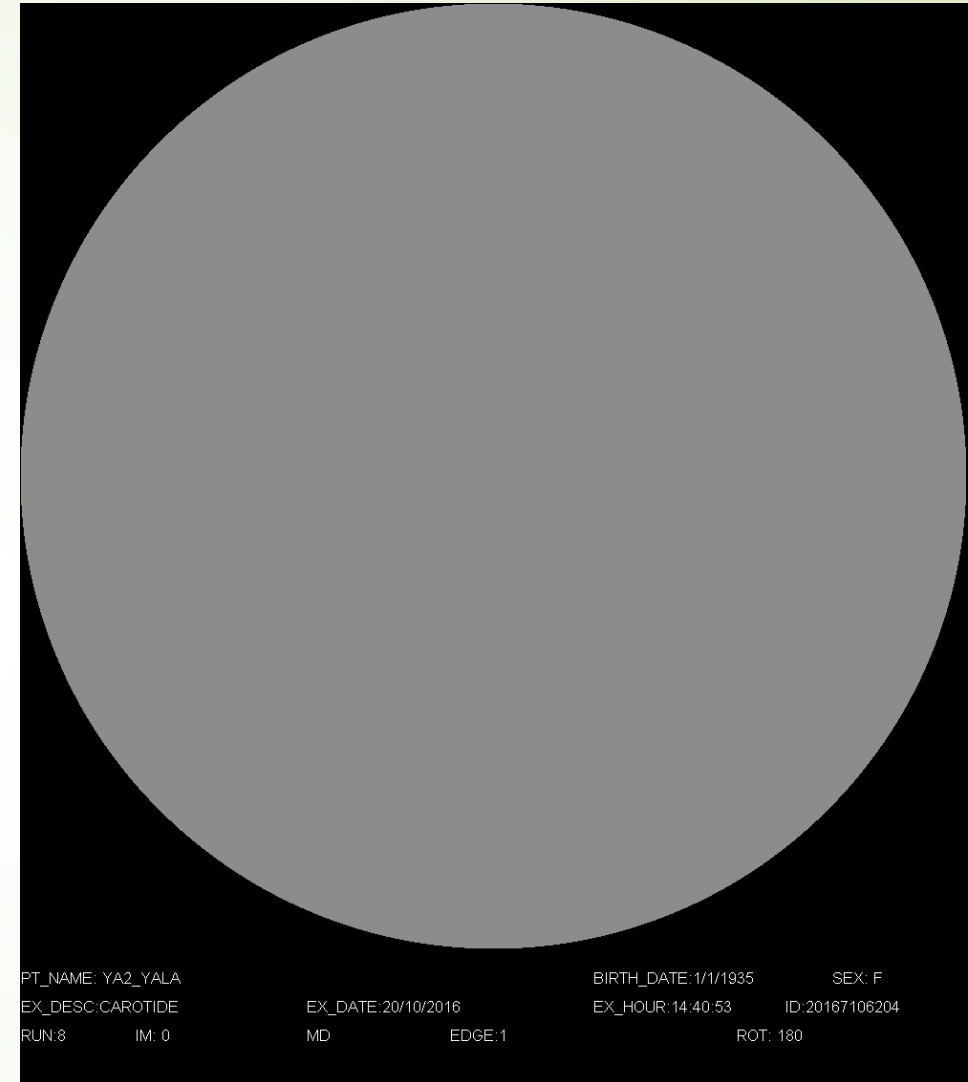
46% multiple lesions



Case 1



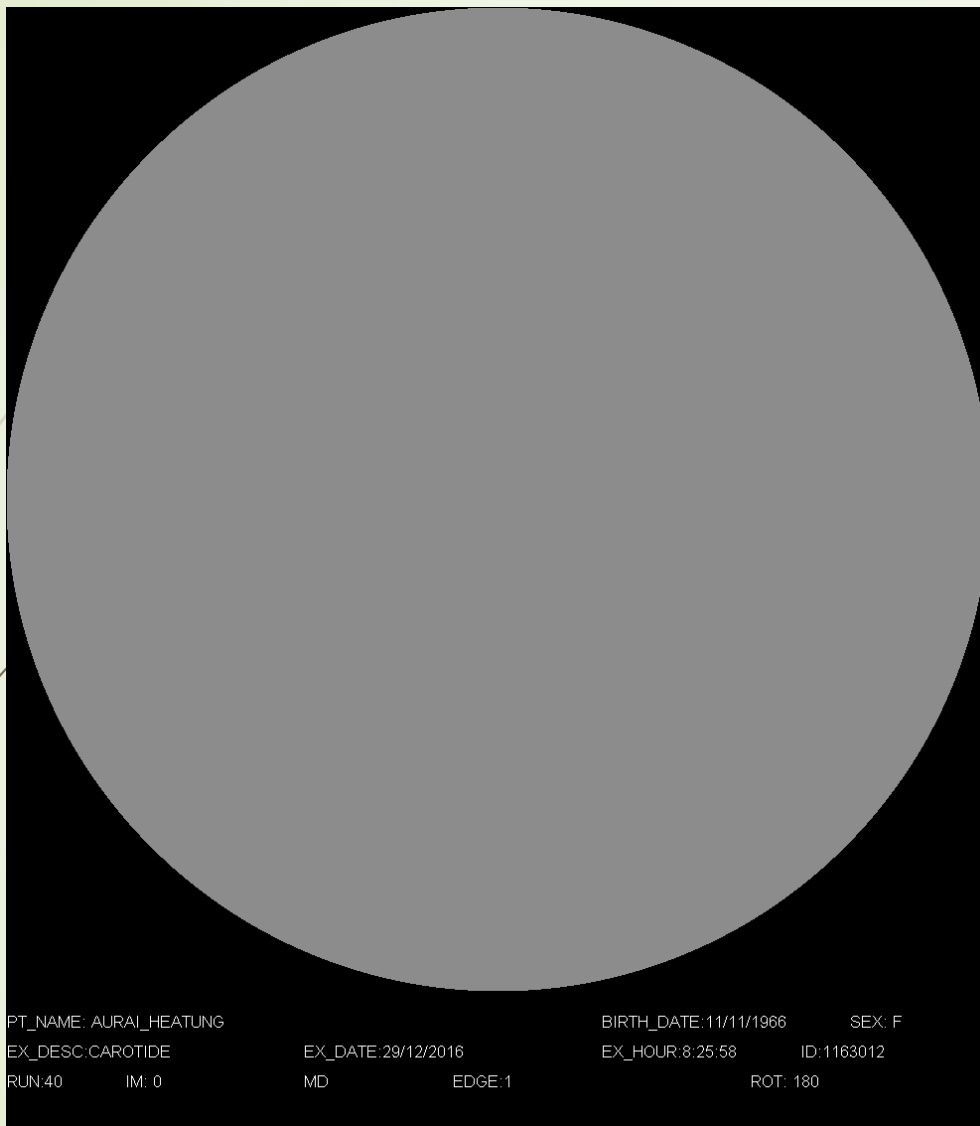
1st angiogram



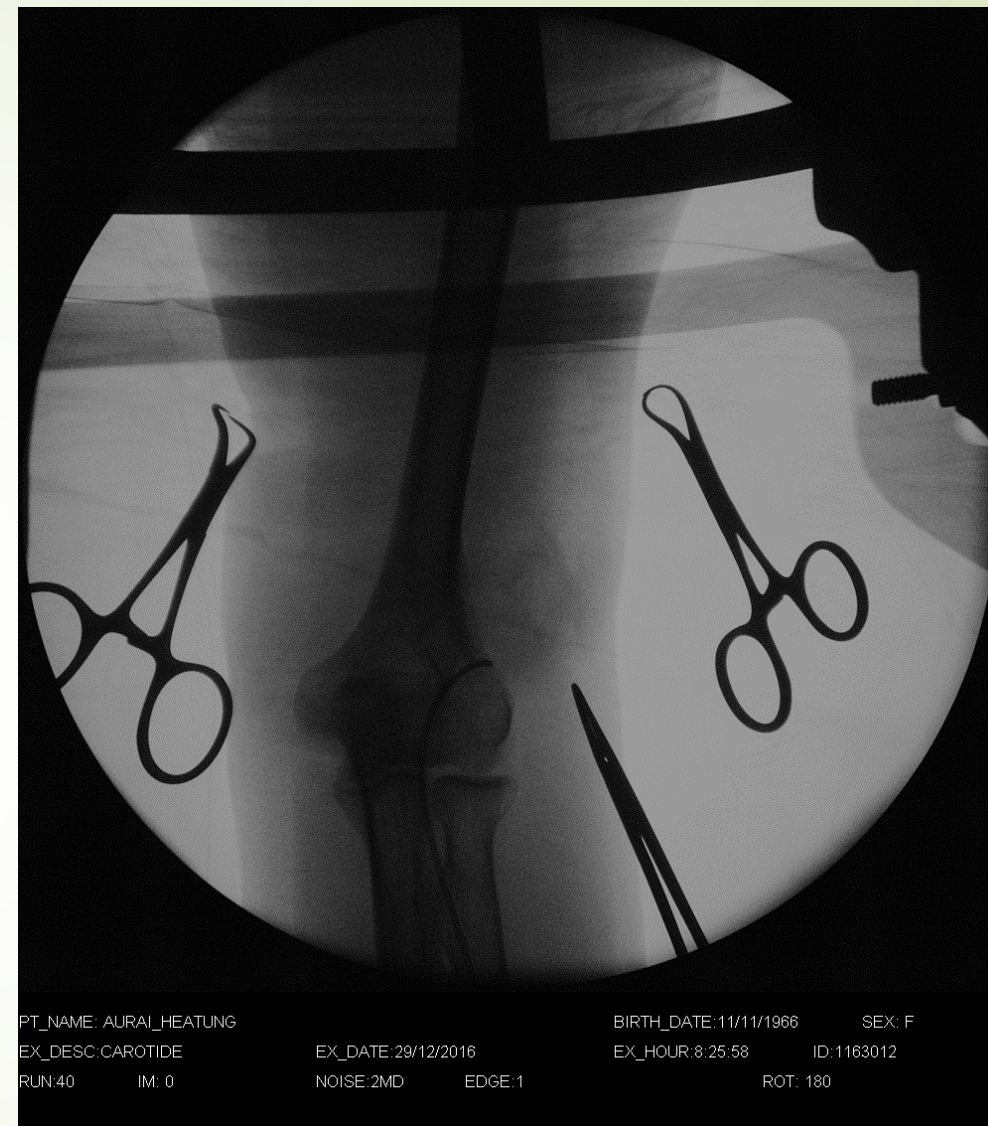
Final angiogram



Case 2



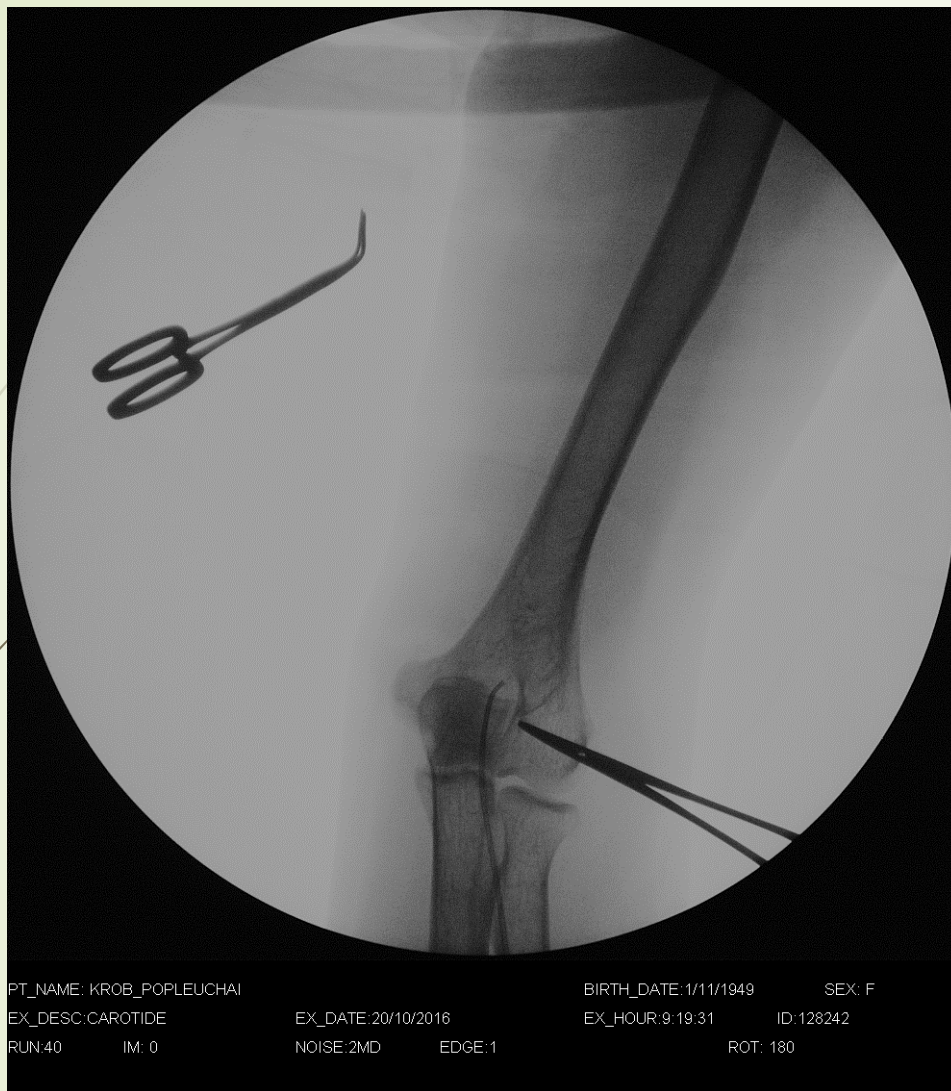
1st angiogram



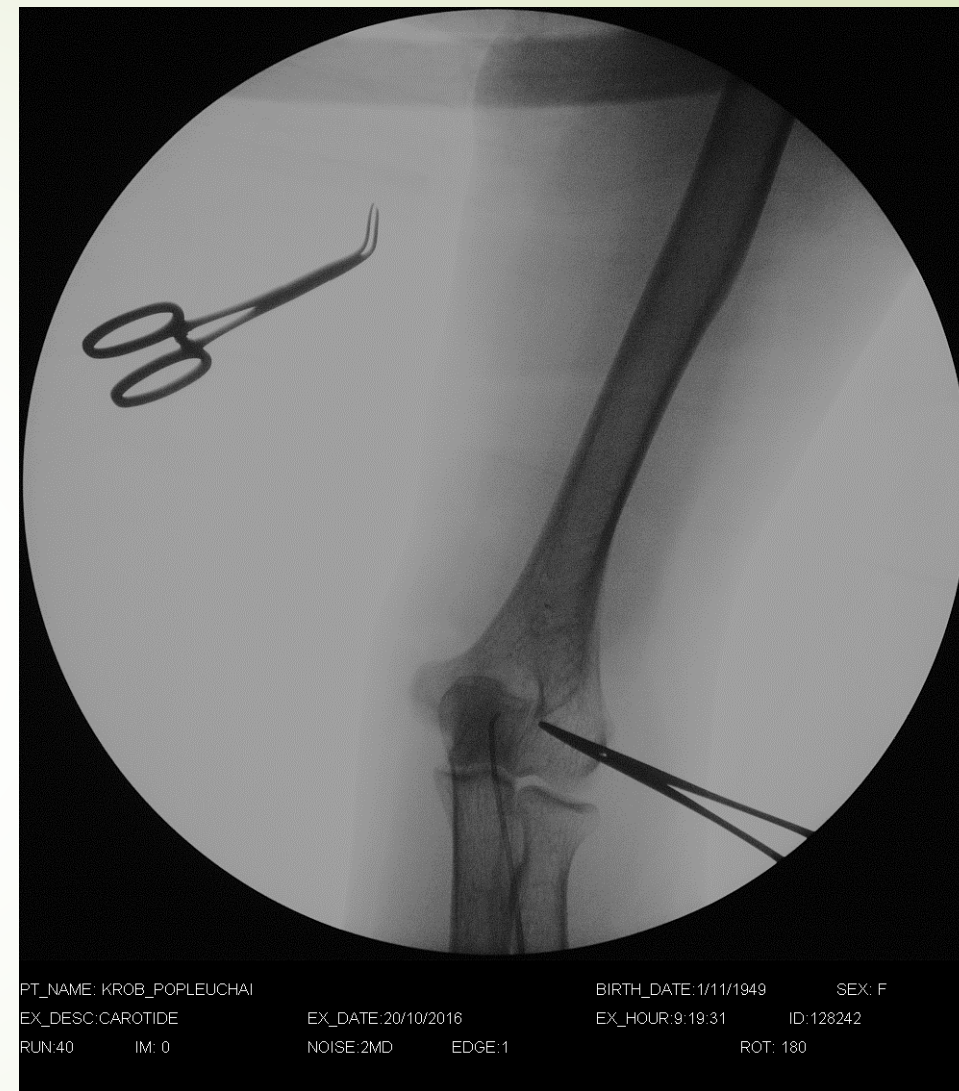
Final angiogram



Case 3



1st angiogram



Final angiogram



Prevention of primary failure: recommendation from up to date

- ▶ The algorithm that appears to have the best chance of decreasing the incidence of primary failure while increasing the prevalence of AV fistulas

- 1.starting early
- 2.doing vascular mapping
- 3.careful selection of a surgeon
- 4.evaluation of all newly created AV fistulas at four weeks
- 5.aggressive program of salvage for primary failures



Thank you for your attention