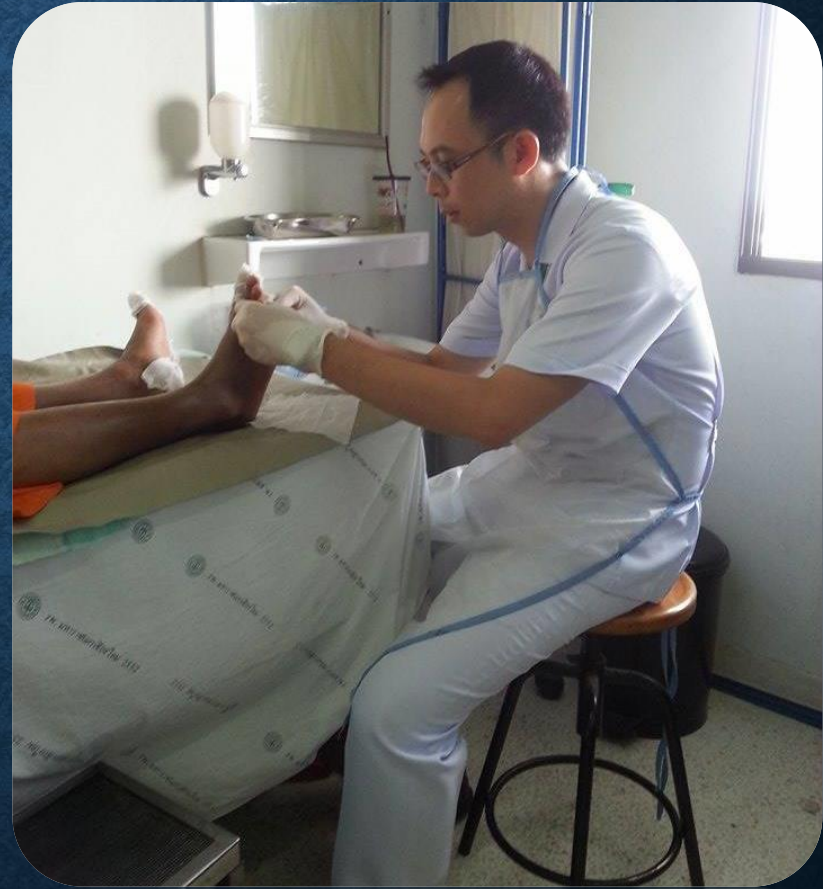
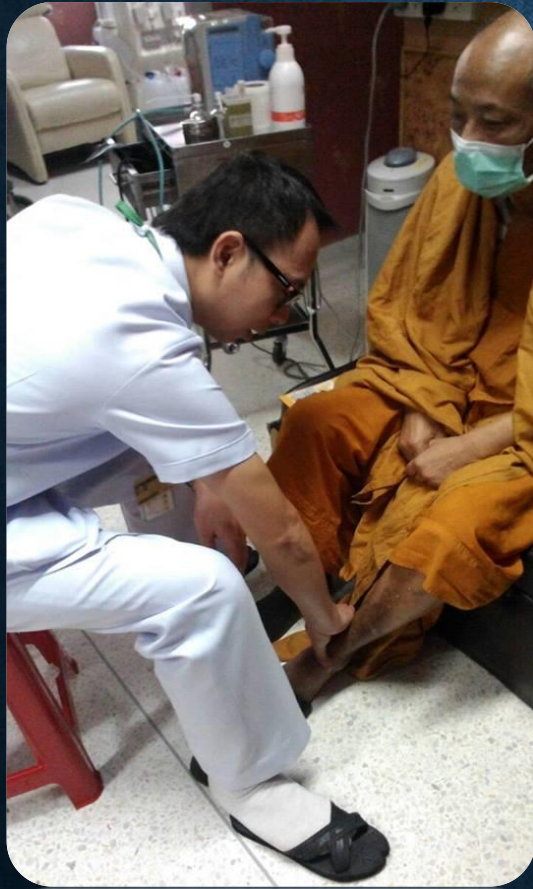
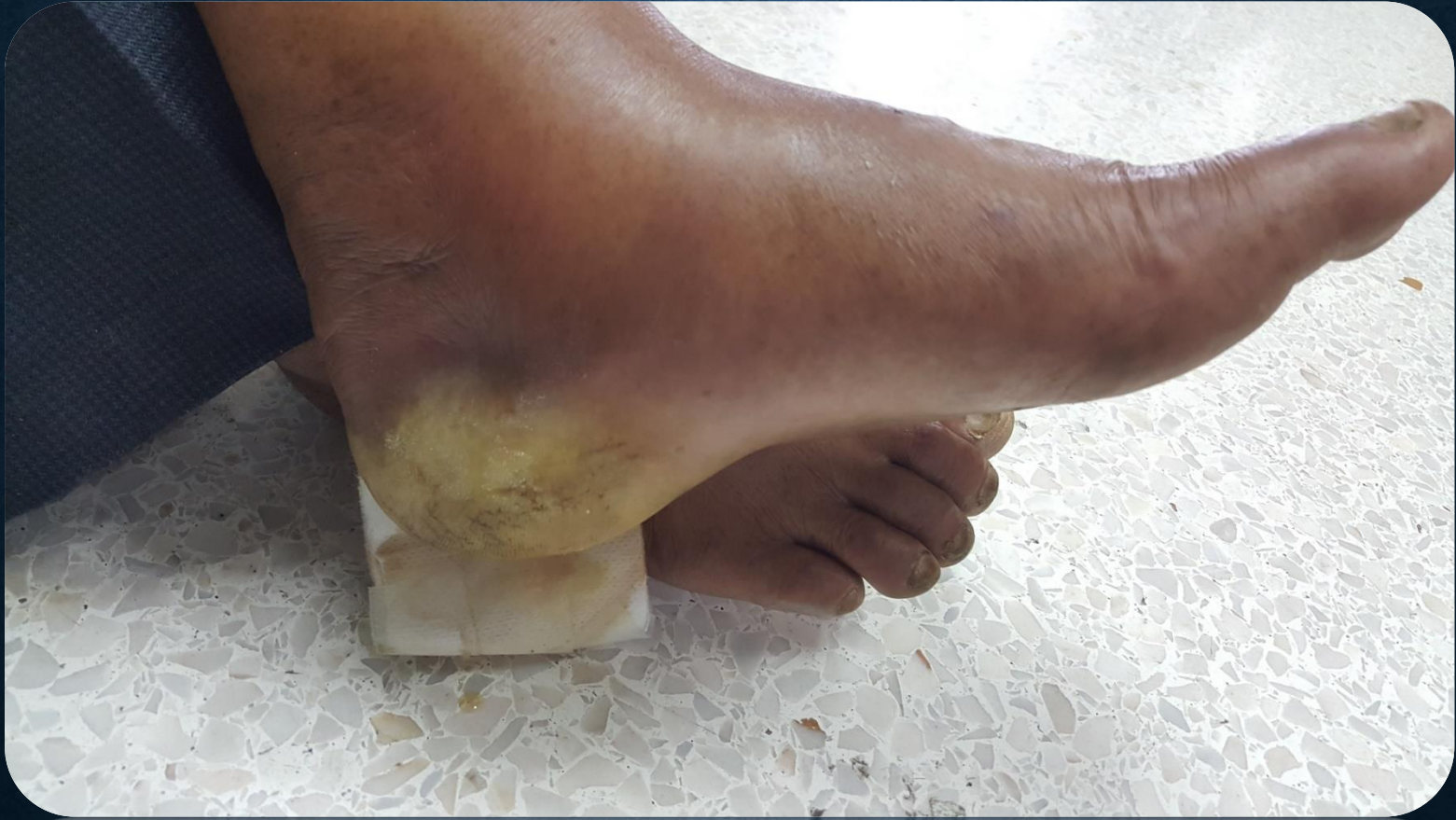# **Case discussion: Difficult case in diabetic foot infection and shoe**

Bumnet Saengrut RN, MSN, dip. APGN

Nursing division, Maharaj Nakorn Chiang Mai Hospital

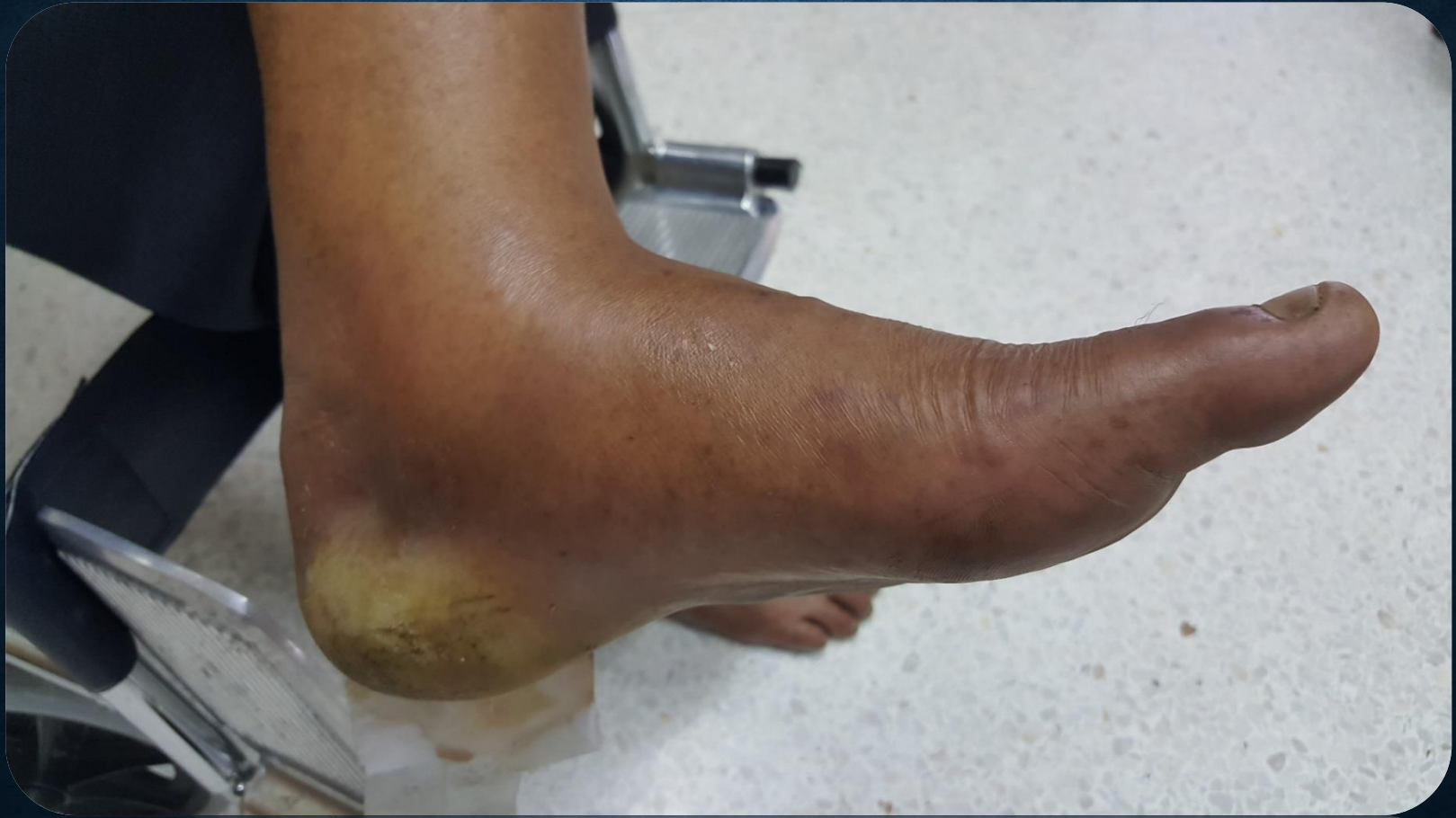# Diabetic Foot Ulcer Prevention & Care

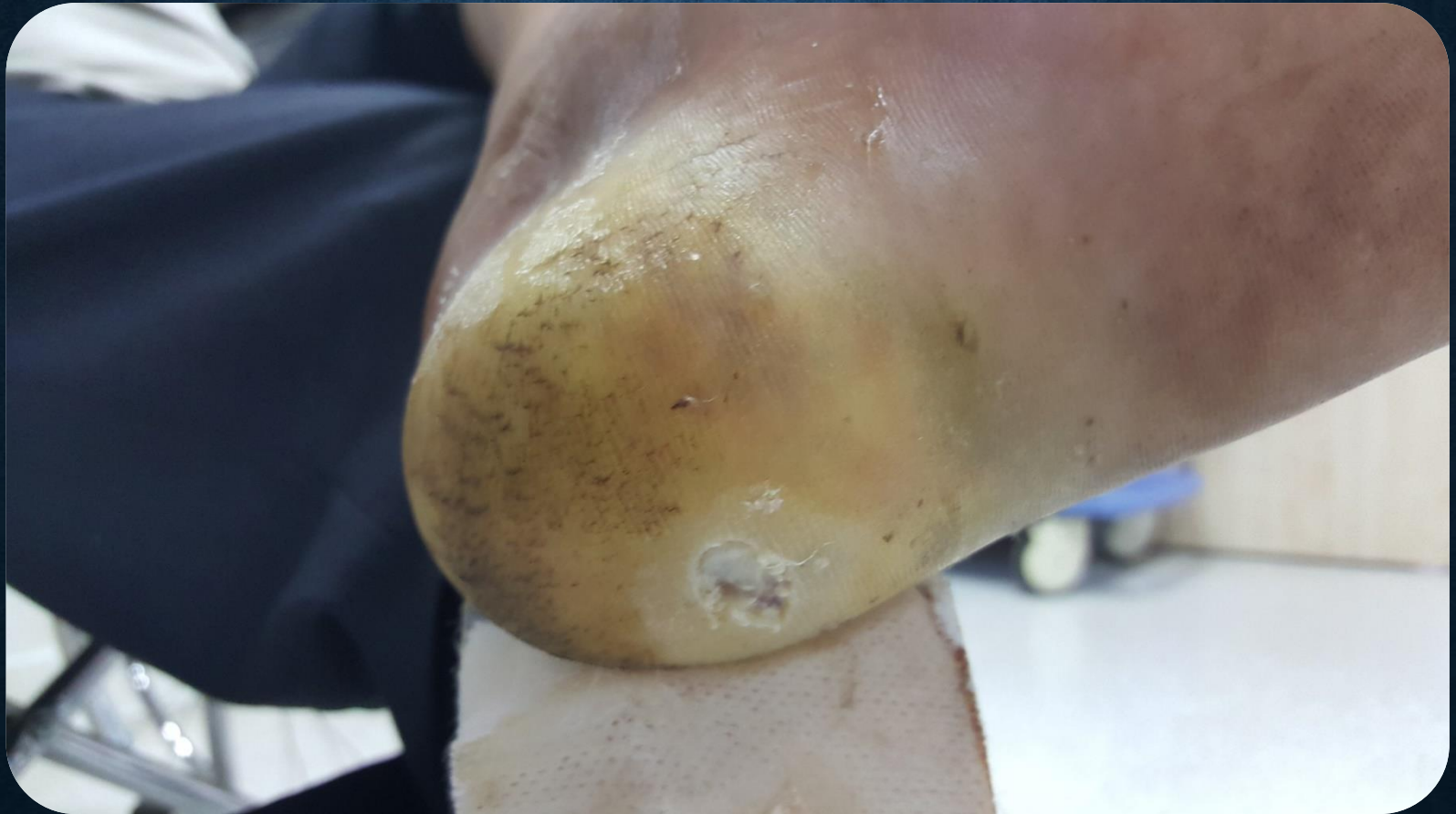


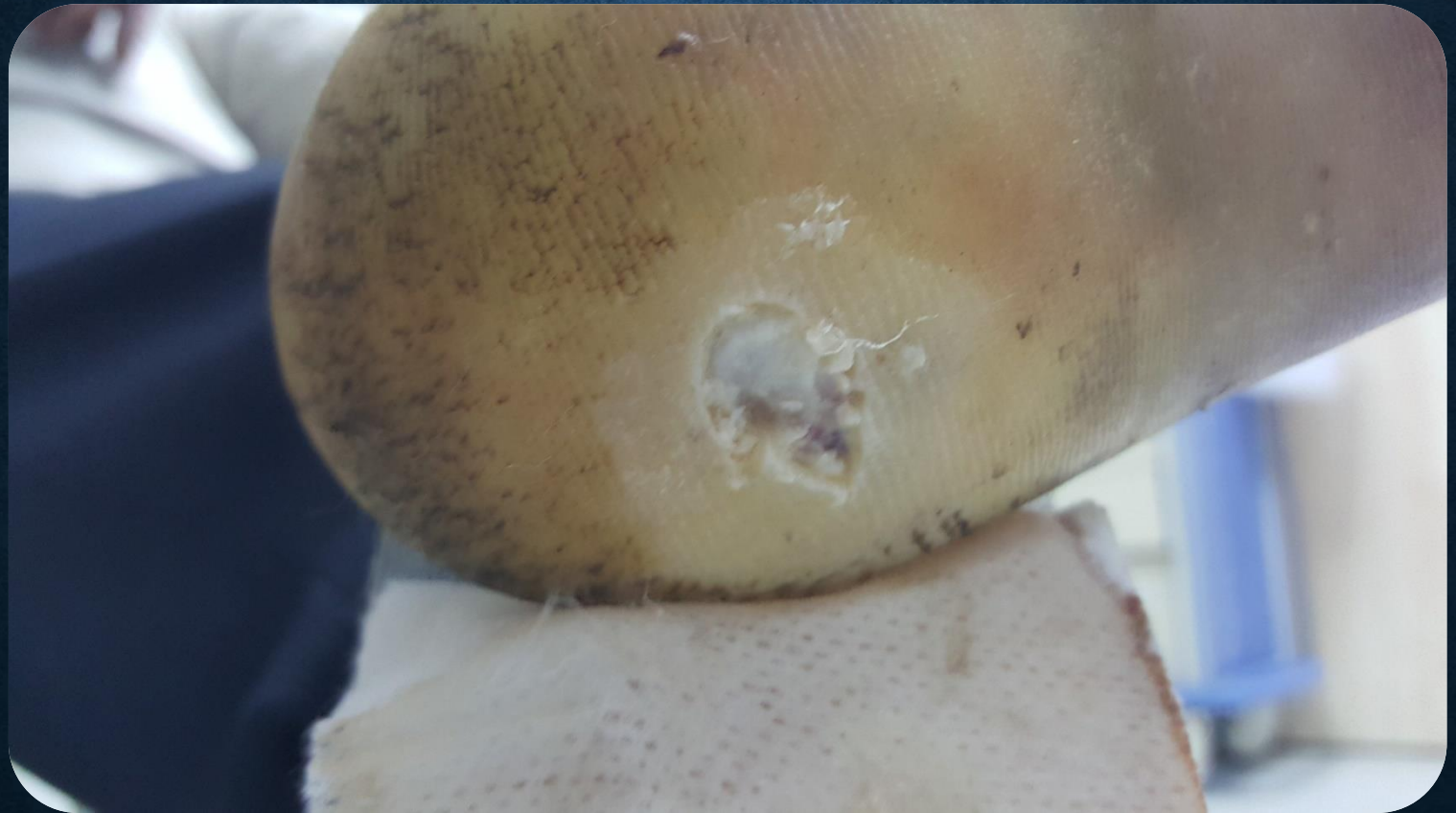
# History

- Thai male 62 yr old
- DM type2 poor controlled, HTN, DLP
- Infected left foot from stepped on a nail 2 week PTA
- Primary Health Care:
  - Dressing
  - Dicloxacillin (250) 1\*4 ac, hs



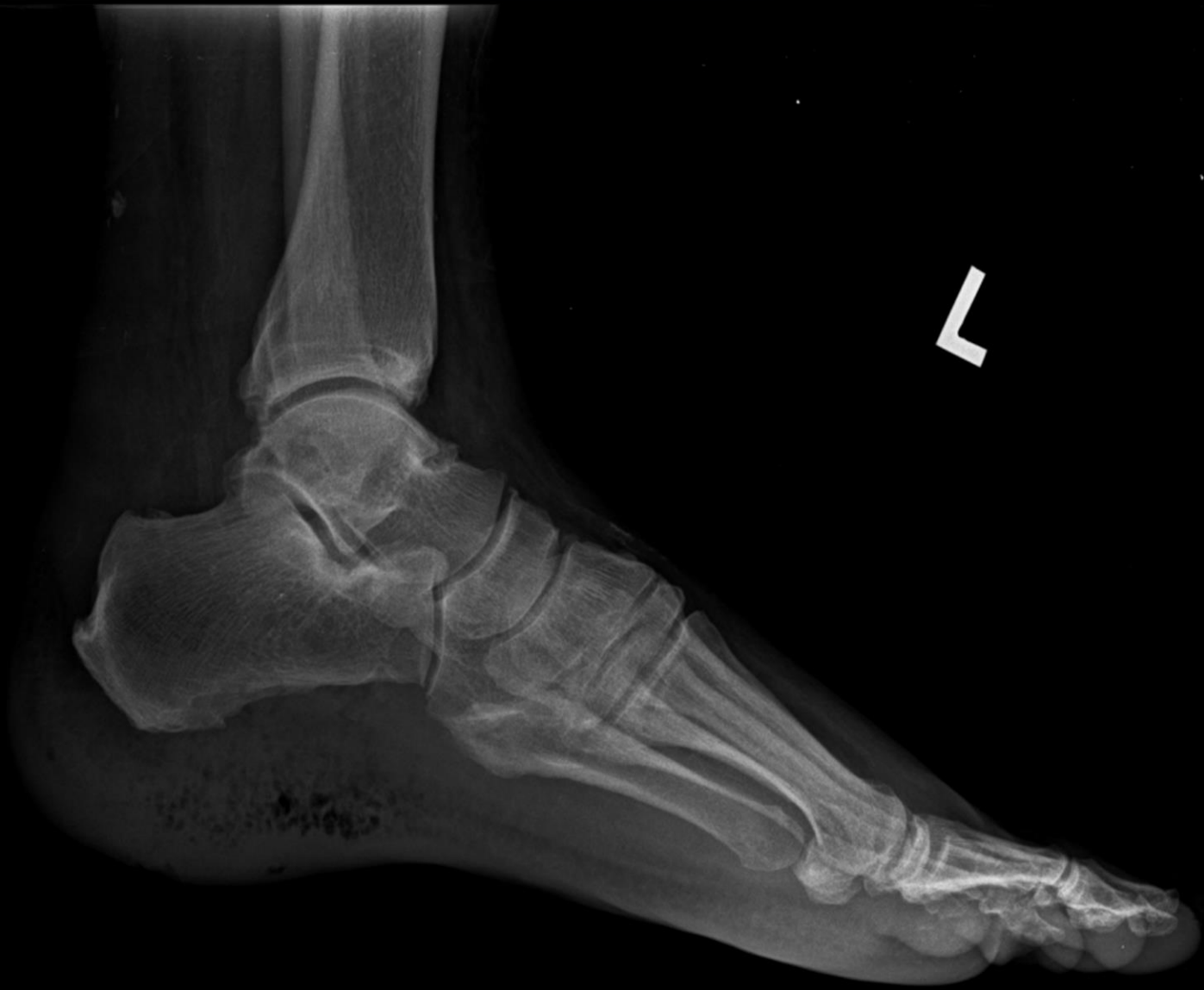



# Data

- HbA1C = 12.04%
- CBC; WBC 16,400
- Body Temperature = 39.3 °C





# Admit

- Set OR for Debridement
- Clindamycin 900 mg IV q 8 hr
- Ciprofloxacin 400 mg IV q 12 hr

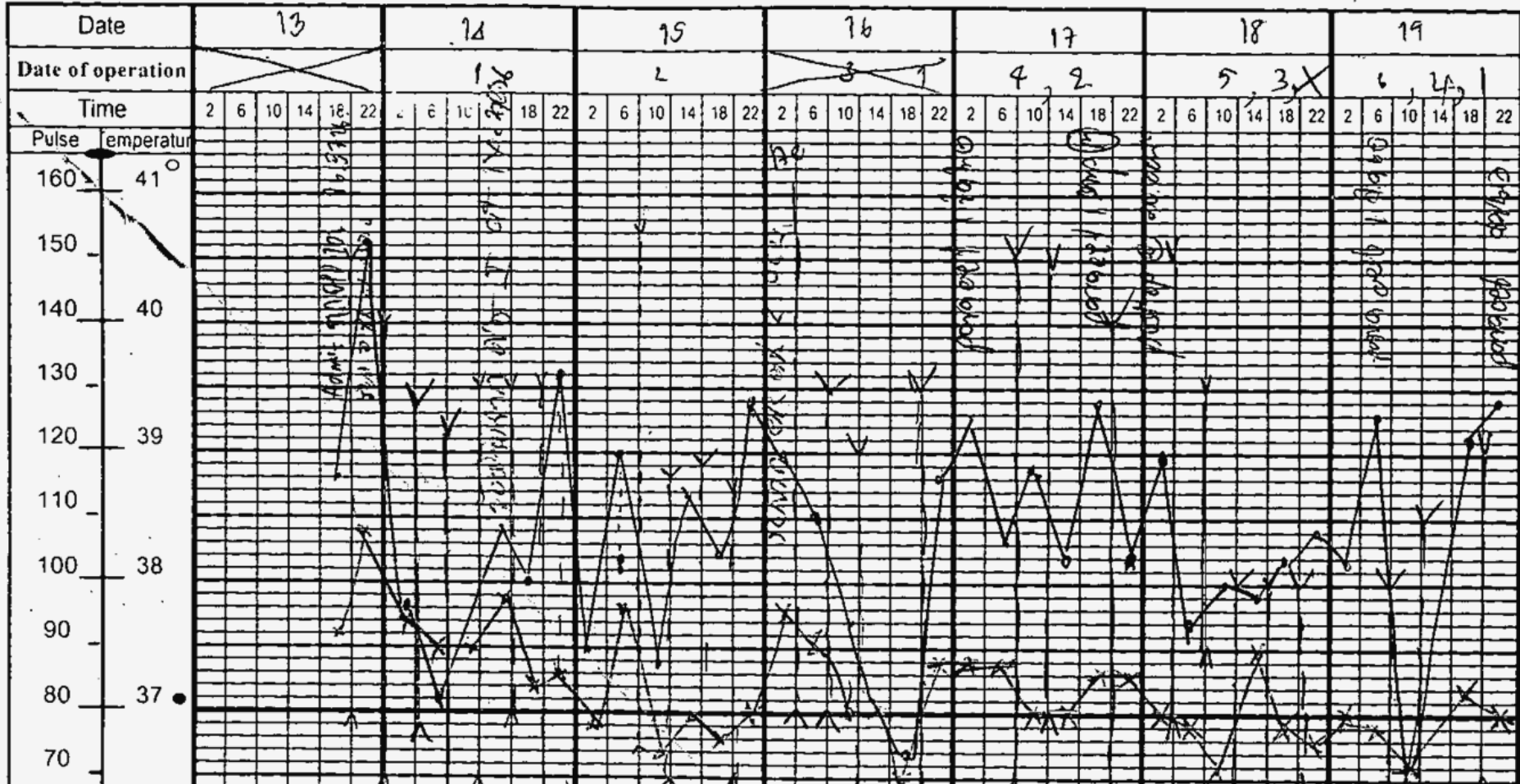
H.N. ....



# Vital Signs Recording Form

Ward..... 187

Month..... March Year..... 2060

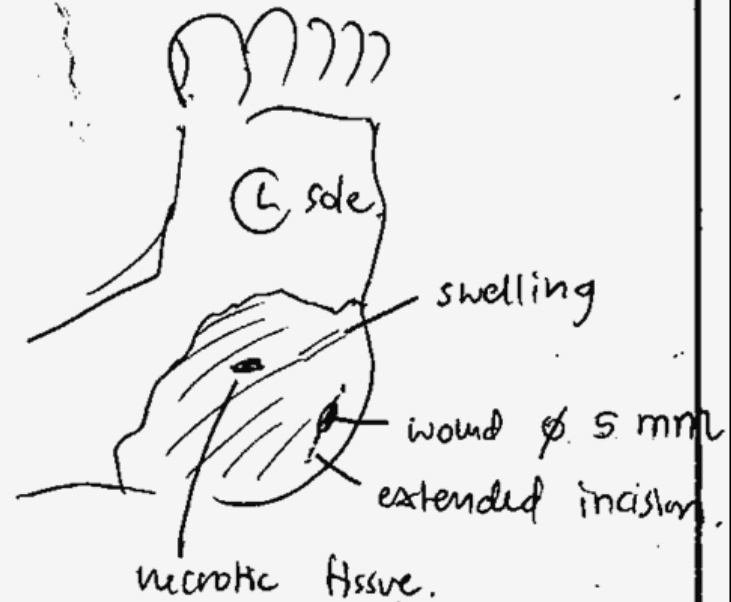


13/03/2017

- Necrotic of epidermis layer of  
Ⓒ heel of foot & purulent discharge  
under epidermal slough.

- Swelling & edematous of subcutaneous  
tissue at heel area, not involve to  
bone. (probe to bone test here).

- Good blood supply to tissue of Ⓒ  
foot.



Drawing

15/03/2017

- Infect. DM Foot at ~~heel~~ Heel.

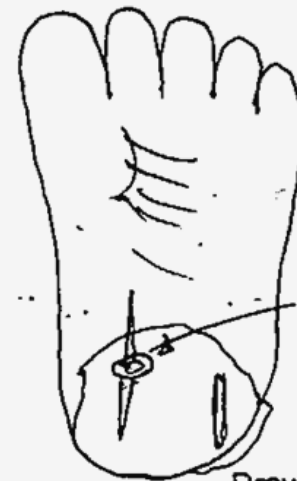
$\phi$  ~ 6 cm. Fluctuating, swelling.

- I & D  $\rightarrow$  Pus ~ 5 ml.

yellow, foul smell.

- No pus pocket at plantar fascia.

- Pus for G/S, C/S



external opening  
with debris tissue

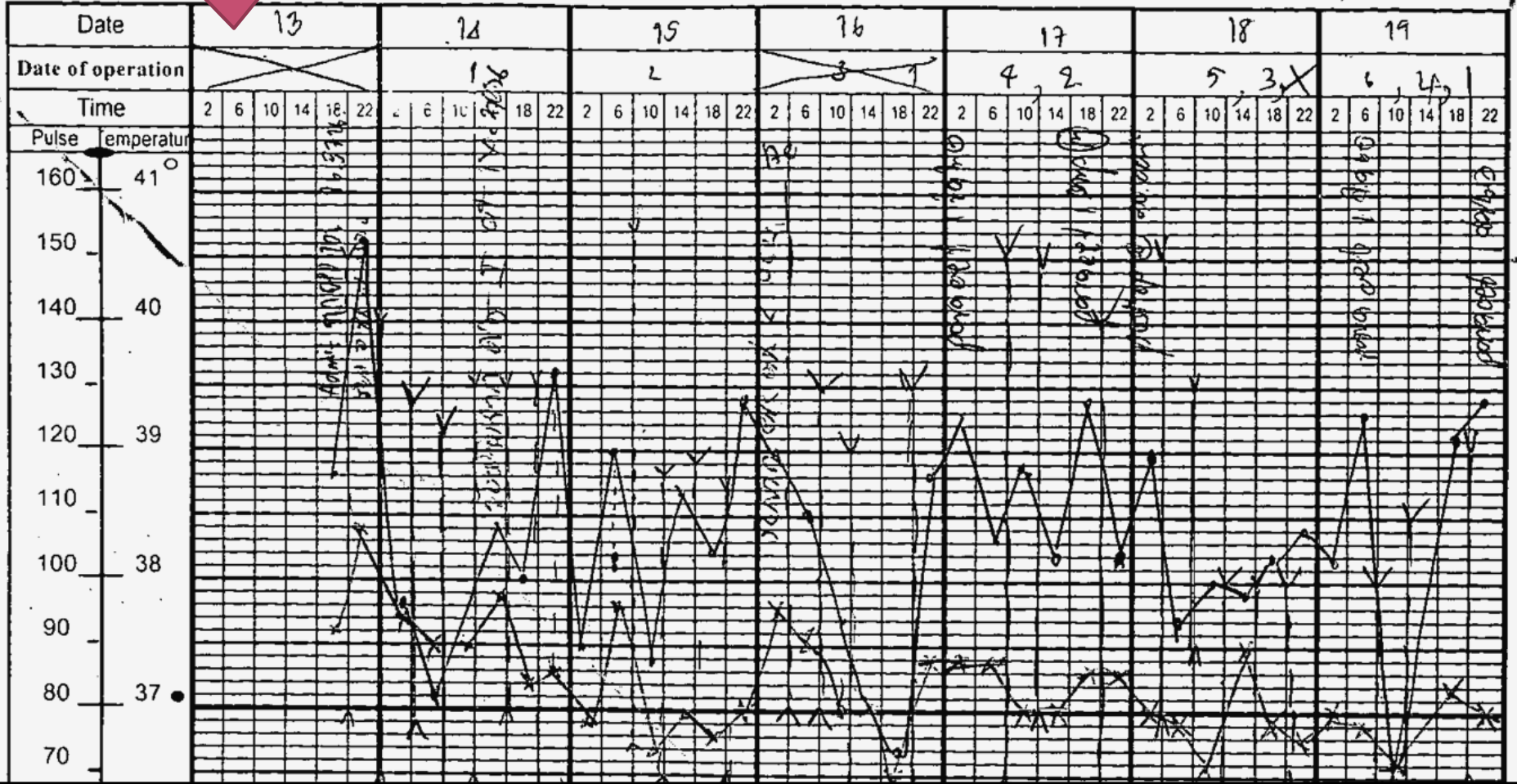
Drawing

Ciprofloxacin  
Clindamycin

MEROPENEM

Vital Signs Recording Form


Ward..... Month September Year 2060



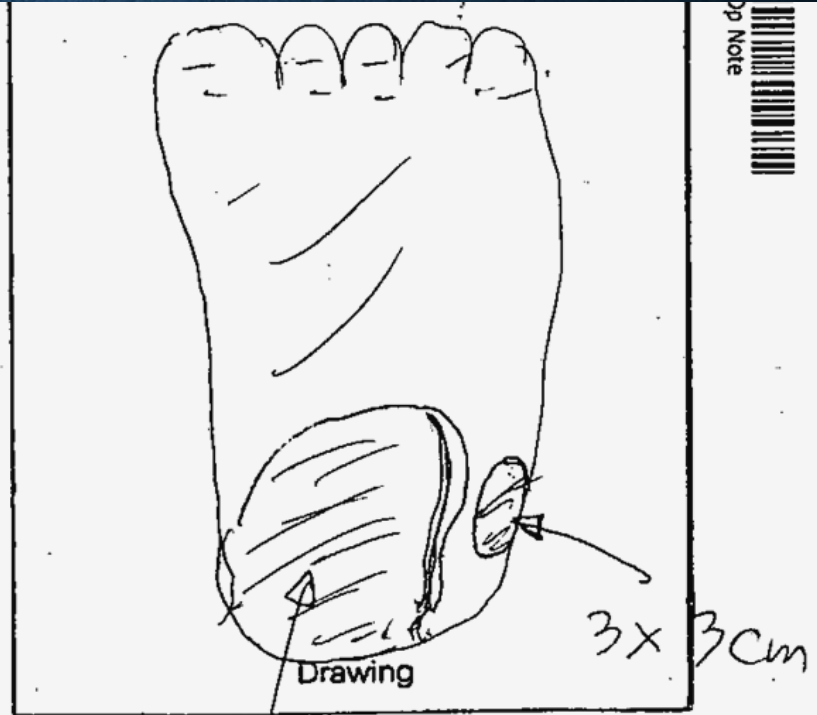
17/3/2017

- Pos sub For G/S, C/S

- Necrotic tissue ~ 8x5 cm.  
with debris.



11wrt Detmide 10/2



8x5 cm.

09:001/1



al Lab)Routine Culture

**Hn**

2812202

⌘ 62 ↓

**Room**

PRI413

16-03-2560 00:02

16-03-2560 : 0:0

16-03-2560 00:20

19-03-2560 11:05

#	Qty	Code	Organism
1	Few	KSLPM	Klebsiella pneumoniae
2	Few	ETRCA	Enterobacter cloacae

#	Code	Antibiotic	Result
1	ST	Sulfamethoxazole/Trimethoprim	S
2	AN	Amikacin	S
3	AU	Amoxicillin/Clavulanic Acid	S
4	TZ	Piperacillin/Tazobactam	S
5	CX	Cefotaxime	S
6	CZ	Ceftazidime	S
7	IP	Imipenem	S
8	ME	Meropenem	S
9	ETP	Ertapenem	S
10	OF	Ofloxacin	
11	CI	Ciprofloxacin	S
12	LX	Levofloxacin	S



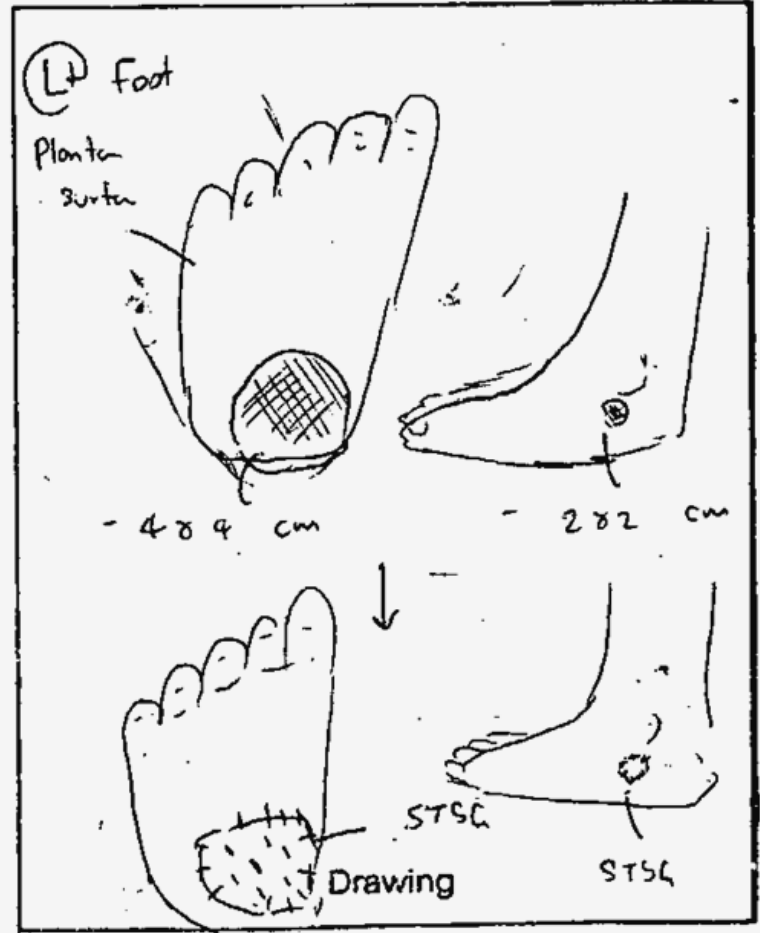
23/04/2017

- Crenulation wound ~ 4 x 4 cm

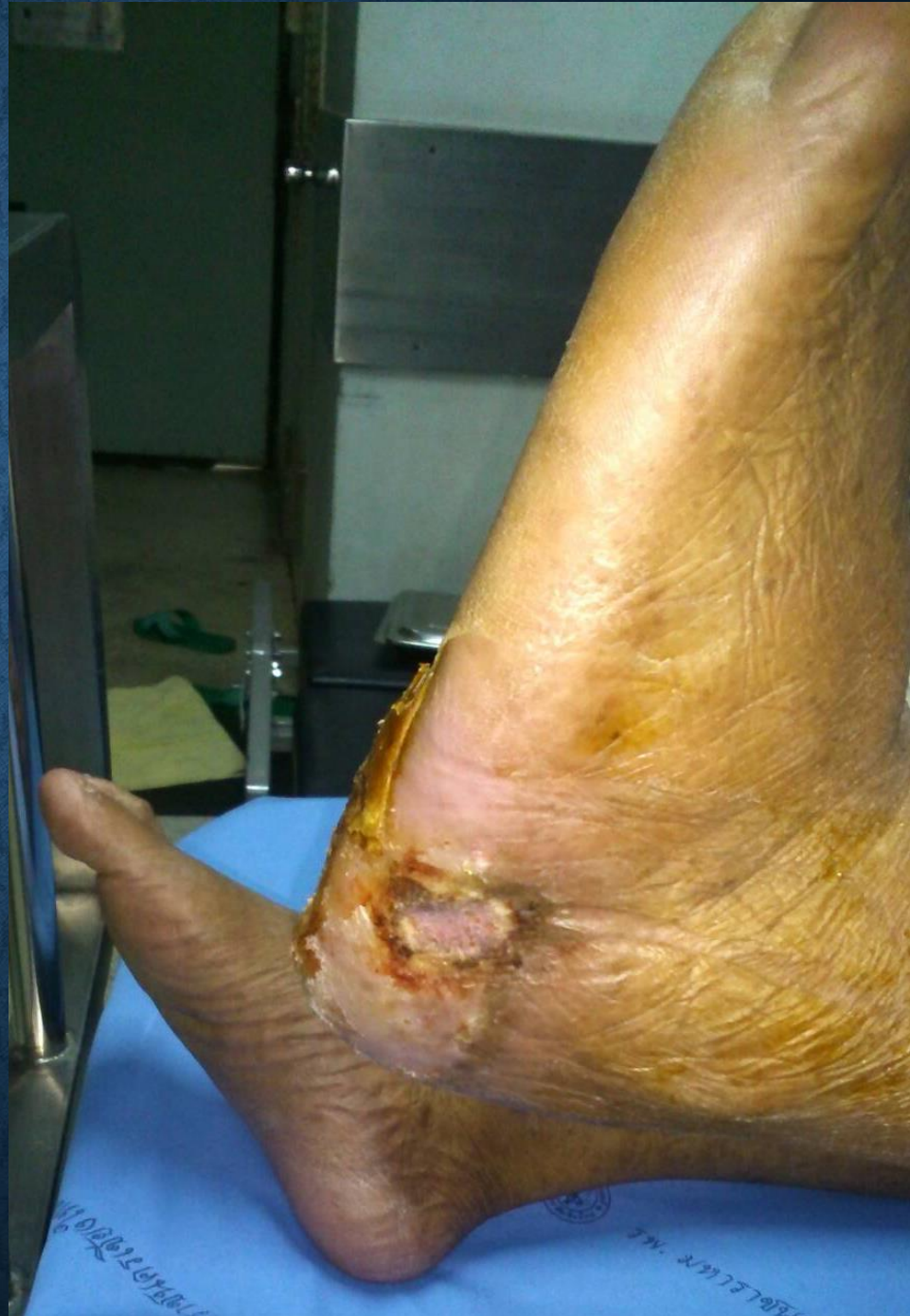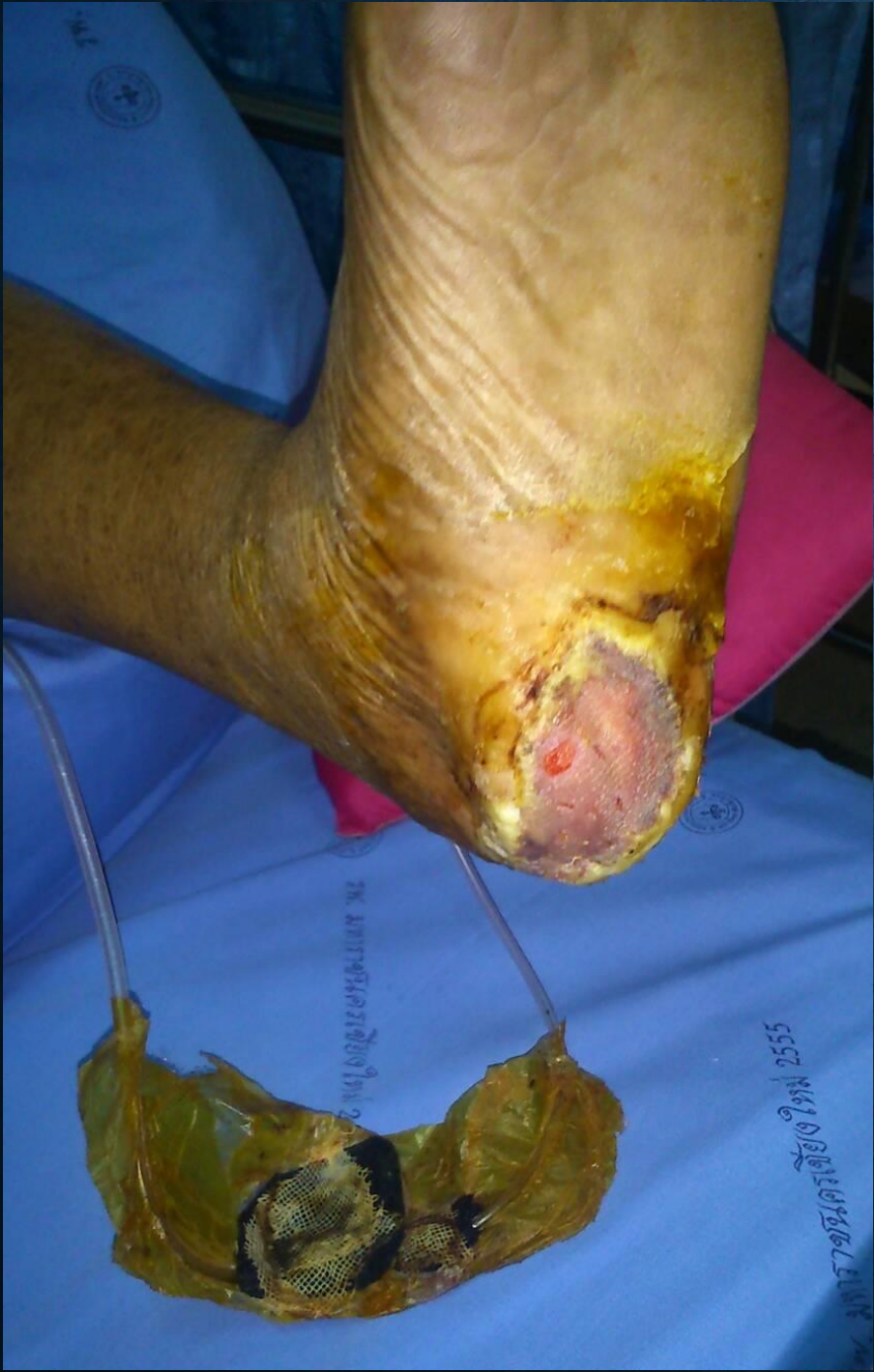(L) heel and ~ 2 x 2 cm

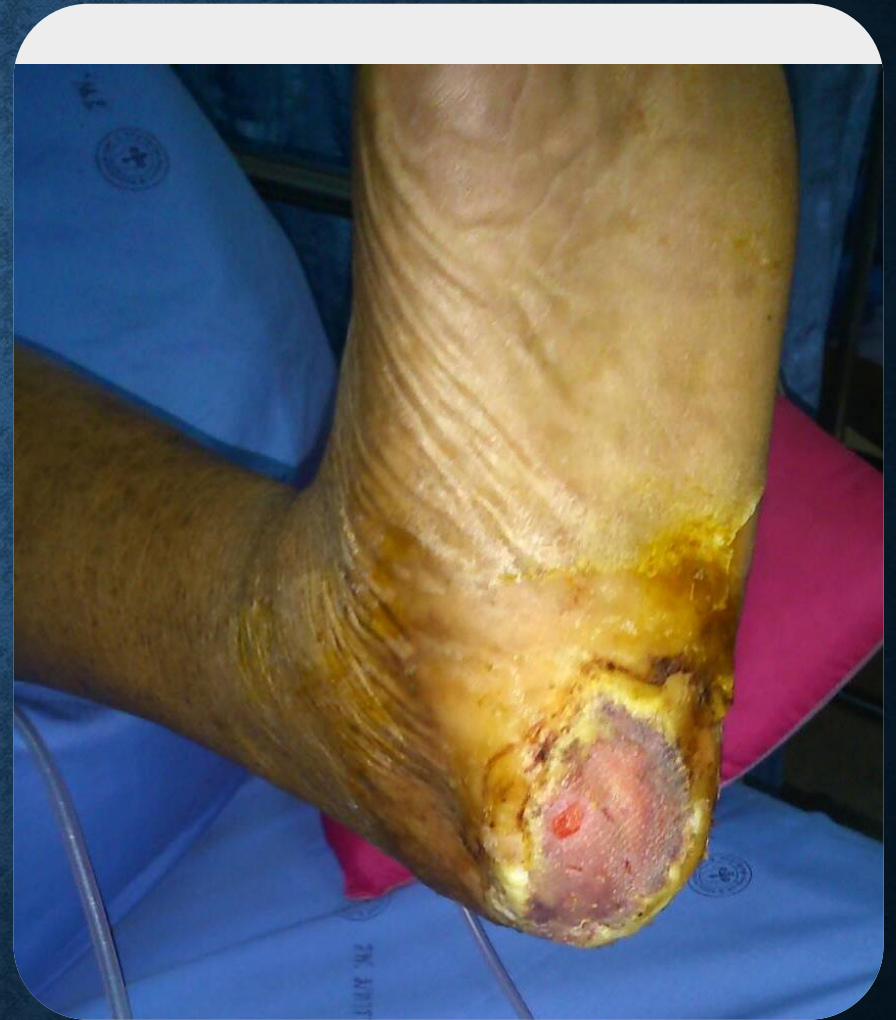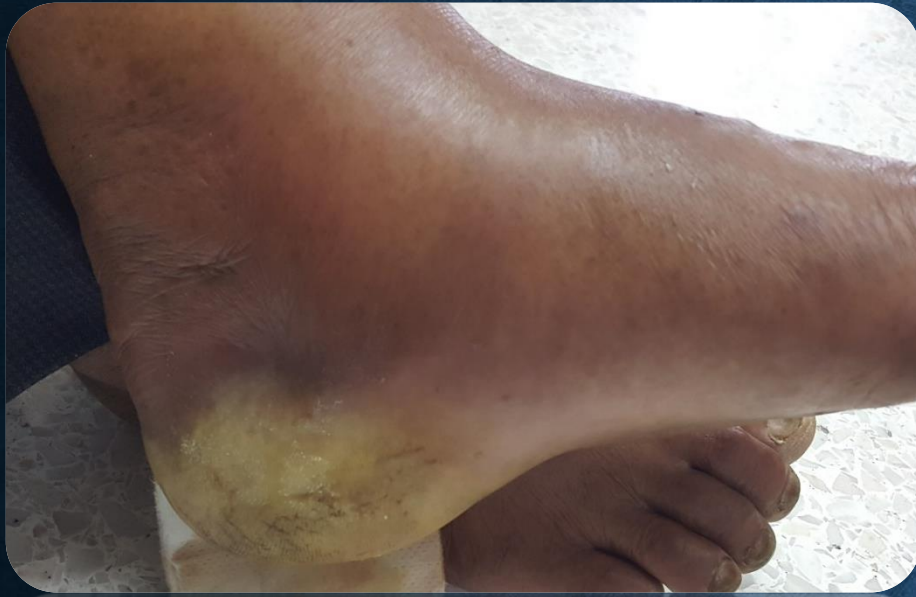(L) lateral side of foot

STSG & vacuum dressing



- **Consult Rehab Plan Shoe modification**
- ผู้ป่วยต้องชำระเงินเอง **2,600.-** สิทธิประกันสังคมเบิกได้ **800.-**
- ใช้ **walker** ลงน้ำหนักที่ฝ่าเท้า






• LOS 49 days

S/P skin graft @ heel .

27 H/O H/O sumitranolol

H/O donor ISA heel .




พริบผิวงา

@ LP heel : dry , no discharge

DM foot (L) heel.

Rx shoe hist (R) ribbon walk assist.

(L) off foot, hind foot.



Check at shoe mod.

hide ✓

